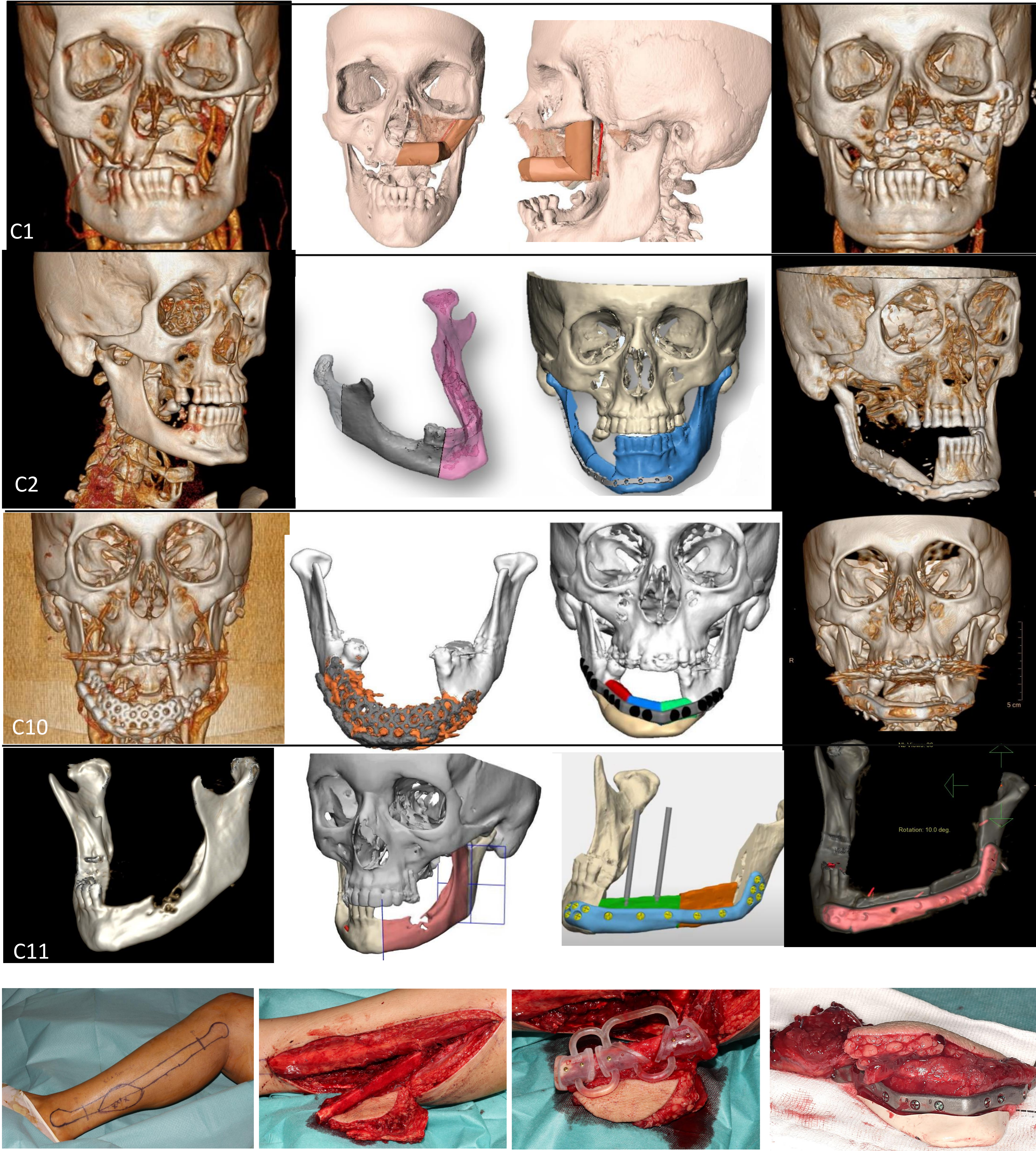


Fibular free flap with cutting guides and prebent plates for maxillo-mandibular reconstruction

Pérez E (*); Andrés C (*); Caja P (*)

(*) Oral & Maxillofacial Department. Hospital Universitario Cruces, Bizkaia, Spain.



Introduction

The fibula free flap has become the gold standard in maxillo-mandibular reconstruction since it was first reported by Hidalgo et al in 1989. In recent years, the advances in computer-assisted surgery (CAS) and computer-aided design/manufacturing (CAD/CAM) technology has improved the strategy for reconstructive craniofacial surgery.

Aims/objectives

Series of cases of primary or secondary reconstruction surgeries after tumoral ablation between the years 2013-2020.

Material and methods

- ✓ **Preoperative imagen techniques:** Head-neck-thorax and lower extremities Computed Tomography Angiography.
- ✓ **Surgical planification** from 3D reconstructions.
- ✓ **Design:** Computed aided Design and Manufacturing (CAD-CAM) **cutting guides** for donor and receptive sites.
- ✓ **Osteosynthesis:** **Preformed** titanium reconstruction plates 2.0 and low-profile miniplates.
- ✓ Patient and reconstruction's stereolithographic **models**

Results

- ✓ Actual softwares allow the **planification** of complex anatomical defects of bone and soft tissues.
- ✓ The technique **minimize bench surgery:** fibular osteotomies and plate fixation can be performed in-vivo.
- ✓ Prebent plates **saves operative time** and prevents deformities, malocclusion and condyle dislocation.
- ✓ Intraoperative **malignant pathology** findings can lead to insufficient surgical margins or suboptimal reconstruction.
- ✓ **Communication ingeneer-surgeon.**
- ✓ **Planification times and costs** are higher than free-hand reconstructive surgery.

Conclusion

The fibular flap allows the reconstruction of big maxillofacial defects and supplies bone support for aesthetic and functional rehabilitation. CAD-CAM technology provides surgical assistants that make the surgery easier, quicker, safer and more predictable.

C	G	Age	To b	OH	CVDR F	Oncological history	Previous treatments	Disease (stage/subtype)	Receiving area	Neck	Flap	Side	Frag	RP	AA	VA	Closur e	H&N Comp	LE Comp	Evolution	FU
1	F	49y	++	+	-	OSCC gum Q1 pT4Nxm0 G1	Hemimax (Iib) & Temporalis flap	Oro-antral fistula	SR & debridement	Vessel Prep Tracheo	OMC	L	3	4 (MP)	Facial (T-T)	Facial (T-T)	Direct	Intolerance osteosynthesis	-	No recurrence	4y2m
2	M	51y	+	+	+++	-	-	OSCC gum Q4 pT4N0M0 G2	SM 4.3- sigmoid notch	Vessel Prep FND uni Tracheo	OFC	L	2	1	Thyroid (T-T)	TLF Tr (T-T)	STSG	Cervical seroma	Equine foot	RT (60Gy)	4y6m
3	F	47y	-	-	+	Unicystic ameloblastoma Q3	Local (x3)	Recurrence	SM 4.3-4.6	Vessel Prep Tracheo	OFC	L	1	1+1 (MP)	Facial (T-T)	Facial (T-T)	Direct	-	-	No recurrence Implant rehabilitation	6y2m
4	M	63y	++	++	-	OSCC floor of mouth Q3 pT4N1M0 Gx	MM 3.4-3.8 + FND uni + RFFF + Tracheo + RT (62 Gy)	Osteoradionecrosis	SR & debridement	Vessel Prep Tracheo	OFC	L	2	1	Facial con (T-T)	Facial con (T-T)	Direct	-	-	No recurrence Implant rehabilitation	2y6m
5	M	54y	+++	++	+	OSCC gum Q3 pT4N3M0 G2	SM 3.3-angle + RND + Pectoralis flap + Tracheo + RT (70Gy) + CISx2	Osteoradionecrosis	SR & debridement	Vessel Prep Tracheo	OFC	L	2	1	Facial con (T-T)	TLF Tr con (T-T)	STSG	Intolerance osteosynthesis	-	No recurrence	3y5m
6	M	53y	++	++	++	OSCC tongue pT3N0M0 G2	Hemiglo + FND uni + Tracheo + RFFF + RT (66Gy)	Osteoradionecrosis	SM 4.2-3.8	Vessel Prep Tracheo	OFC	L	2	1	Thyroid con (T-T)	TLF Tr (T-T)	STSG	Intolerance osteosynthesis	-	No recurrence	6y5m
7	M	24y	+	-	-	-	-	Odontogenic Myxofibroma Q3	SM 3.3-condylar neck	Vessel Prep Tracheo	OFC	L	3	1	Facial (T-T)	TLF Tr (T-T)	STSG	-	-	No recurrence	3y9m
8	M	64y	-	+	-	OSCC gum Q3 & buccal mucosa pT1N0M0 Gx	Local resection + direct closure	OSCC gum Q3 cT4n2bM0	SM 3.3-3.8	Vessel Prep FND uni Tracheo	OFC	L	1	1	Facial (T-T)	TLF Tr (T-T)	Direct	Flap loss. Oro-cervical fistula. Rescue flap: Pectoralis major	Dehiscence & infection	Tongue OSCC recurrence pT1pN1M0: subtotal glossectomy + FND RT (66Gy)	3y10m
9	F	40y	-	-	-	-	-	OSCC retromolar trigone Q3 pT4aN2bM0	SM 4.6 – sigmoid notch	Vessel Prep FND uni Tracheo	OFC	L	1	1	Facial (T-T)	TLF Tr (T-T)	Direct	-	-	No recurrence	2y6m
10	F	52y	-	-	-	Polycystic ameloblastoma mandibular symphysis & Q4	MS 3.3-4.6 + Custom titanium mesh + ICBG	Intolerance osteosynthesis material	SM 3.5-4.6	Vessel Prep Tracheo	OMC	L	3	1+ PEEK	Facial (T-T)	TLF Tr (T-T)	FTSG	PEEK prosthesis intolerance	FTSG partial loss	No recurrence Implant rehabilitation	1y2m
11	F	65y	+	-	-	OSCC tongue x2 pT1N0M0	Local resection + direct closure	OSCC gum Q3 & left mandibular body PpT4aN0M0 sarcomatoid transformation	SM 3.3 – sigmoid notch	Vessel Prep FND uni Tracheo	OFC	L	2	1	Thyroid (T-T)	TLF Tr (T-T) & ext Yugular (T-T)	FTSG	-	-	Mandibular symphysis OSCC recurrence RT 69Gy CT CDDP x2	1y5m
12	M	66y	+	-	-	-	-	OSCC gum Q3 pT3N1M0	SM 3.4- md angle	Vessel Prep FND uni Tracheo	OMC	R	1	1	Facial (T-T)	Lingual (T-T) & IYV (T-L)	FTSG	Plate displacement	FTSG partial loss	RT 60Gy	6m
13	F	66y	-	-	-	-	-	OSCC gum Q3 pT4N0M0	SM 3.4 – L sigmoid notch	Vessel Prep FND uni Tracheo	OMC	L	1	1	Facial (T-T)	TLF Tr (T-T) & ext Yugular (T-T)	STSG	-	-	RT 60Gy	3m
14	M	55y	-	-	-	-	-	OSCC gum Q4 pT4aN0M0	SM 4.6- sigmoid notch	Vessel Prep FND uni Tracheo	OMC	L	1	1	Facial (T-T)	IYV (T-L)	FTSG	-	FTSG partial loss	RT 60Gy	2m

AA: Arterial Anastomosis; C: Case; CT: Chemotherapy; con: contralateral; ext: external; F: Female; FND: Functional Neck Dissection; FTSG: Full Thickness Skin Graft; FU: Follow-up; G: Gender; H&N Comp: Head & Neck Complications; Hemimax: Hemimaxillectomy; Hemiglo: Hemiglossectomy; IGGB: Iliac Crest Bone Graft; IYV: Internal Jugular Vein; L: Left; LE Comp: Lower-Extremity Complications; m: month; M: Male; MM: Marginal Mandibulectomy; OH: Alcohol; PEEK: Polyetheretherketone; Prep: Preparation; Q: Quadrant; RP: Reconstruction Plate; MP: Mini Plate; md: mandible; OFC: Osteofasciocutaneous; OMC: Osteomusculocutaneous; OSCC: Oral Squamous Cell Carcinoma; RT: Radiotherapy; RND: Radical Neck Dissection; SM: Segmental Mandibulectomy; R: right; SR: Surgical Resection; TOB: Tobacco; Tracheo: Tracheostomy; STSG: Split Thickness Skin Graft; TLF Tr: Thyrolynguofacial trunk Uni: Unilateral; VA: Venous Anastomosis; y: year.

Bibliography

1. Lethaus B, Kessler P, Boeckman R, Poort LJ, Tolba R. Reconstruction of a maxillary defect with a fibula graft and titanium mesh using CAD/CAM techniques. Head face med 2010; 6:16
2. Liu YF, Xu LW, Zhu HY, Liu SSY. Technical procedures for template-guided surgery for mandibular reconstruction based on digital design and manufacturing. BioMedical Eng Online 2014.
3. Pellini R, Mercante G, Spriano G. Step-by-step mandibular reconstruction with free fibula flap modelling. Acta Otorhinolaryngol Ital 2012;32:405-409
4. Sanjay Mahendru, Rahul Jain, Aditya Aggarwal, Hardeep S. Aulakh, Ankit Jain, Rakesh K. Khazanchi, Deepak Sarin,
5. CAD-CAM vs conventional technique for mandibular reconstruction with free fibula flap: A comparison of outcomes. Surgical Oncology. Vol 34. 2020, Pages 284-291.
6. Chan A, Sambrook P, Munn Z, Boase S. Effectiveness of computer-assisted virtual planning, cutting guides and pre-engineered plates on outcomes in mandible fibular free flap reconstructions: a systematic review protocol. JBI Database System Rev Implement Rep. 2019 Oct;17(10):2136-2151. doi: 10.111124/BISRI-2017-003875. PMID: 31403550